

Supraspinatus Tendinopathy

VETERINARY ORTHOPEDIC
VOSM
SPORTS MEDICINE GROUP



<http://www.flickr.com/photos/27875041@N02/4659251156/>

Sherman O. Canapp, Jr., MS, DVM, CCRT
Diplomate, American College of Veterinary Surgeons
Diplomate, American College of Veterinary Sports Medicine & Rehabilitation

Veterinary Orthopedic & Sports Medicine Group
10975 Guilford Road, Annapolis Junction, MD 20701
(240) 295-4400 • info@vosm.com • www.VOSM.com
Conveniently located between Annapolis, Baltimore, and Washington, D.C.

Supraspinatus tendinopathy (ST) is a common cause of forelimb lameness in performance, working and active companion dogs. The condition involves injury to the supraspinatus, a major tendon responsible for shoulder extension (reaching forward during walking, trotting or running). See Figure 1. Supraspinatus tendinopathy is a common condition in human medicine as well, particularly in sports involving repetitive overhead motion, such as swimming, tennis, volleyball and baseball. As in humans, ST can be challenging to diagnose and treat, with common recurrence of pain or lameness.

HOW DOES SUPRASPINATUS TENDINOPATHY OCCUR?

In dogs, the most common cause of ST is overuse due to chronic repetitive activity. Activities such as landing from a jump with outstretched forelimbs, quick turns and jump-turn combinations can place the soft tissue structures of the shoulder joint under extreme stress. These maneuvers are routine for companion animals (chasing a squirrel or fetching a ball, e.g.), canine athletes (agility or flyball, e.g.) and working dogs (police, hunting or herding, e.g.).

Repetitive activity puts increased biomechanical load on the tendon, eventually leading to a strain injury. Strain injury results in reduction of strength and flexibility of the tendon, predisposing it to further injury. Eventually, repeated strain causes disruption of the tendon fibers, creating a core lesion. As the condition progresses, a rapidly-growing nodule of scar tissue, called a supraspinatus bulge, often develops within the tendon and compresses the adjacent biceps tendon, further increasing discomfort. In chronic cases, two findings may be present: mineralization within the tendon and/or bony remodeling at the point of insertion.

WHAT ARE THE SYMPTOMS OF ST?

Patients with ST may or may not present with forelimb lameness. They may present with more subtle changes, such as shortened step or stride length or changes in performance. Other patients may present with a weight-bearing lameness that is exacerbated with exercise and heavy activity. Most often, the patient is only lame on one forelimb. At VOSM, a retrospective six-year study of 122 ST patients revealed a 2-to-1 ratio of unilateral to bilateral lameness, respectively. Often, lameness worsens with activity and does not improve with rest and non-steroidal anti-inflammatory medications (NSAIDs). For 42.2 percent of the patients, prior rehabilitative therapy failed to resolve the discomfort and lameness. Study results also confirmed that 75.9 percent of dogs failed to respond to rest and NSAID therapy.

HOW IS ST DIAGNOSED?

Physical Examination

An orthopedic evaluation should be performed by a specialist trained in veterinary sports medi-

vine. Upon physical examination, discomfort is noted during shoulder flexion, which stretches the supraspinatus, and upon direct palpation of the tendon. Shoulder flexion and/or extension may cause tendon spasm. The supraspinatus may also be atrophied, especially in chronic situations.

When moving the forelimb laterally away from the body (shoulder abduction), discomfort and spasm may also be noted if concurrent medial shoulder syndrome is present.

Because the supraspinatus bulge often compresses the biceps, pain is often noted when directly palpating this tendon or stretching the biceps (flexing the shoulder and extending the elbow). This may also indicate a concurrent biceps tendon condition, such as biceps tendinopathy.

Objective Gait Analysis

At VOSM, we perform objective gait analysis (GAITRite/GAITFour) as part of our comprehensive orthopedic evaluation. This objective analysis is reassessed at each post-operative recheck evaluation to monitor lameness or gait abnormality and to ensure your dog is improving. Serial gait analysis is performed to objectively evaluate response to treatment and help direct your dog's therapy rehabilitation program.

Radiographs (X-Rays)

The orthopedic evaluation also includes shoulder and elbow radiographs (x-rays). Shoulder radiographs are performed to rule out other bony disease processes and to identify mineralization

within the supraspinatus tendon or bony remodeling at the point of insertion. In our study of 122 dogs, mineralization was noted in almost 25 percent of the patients. In some cases, mineralization was noted in both shoulders, even when the patient only presented with unilateral lameness.

Elbow radiographs are performed to identify any obvious concurrent conditions that may also be contributing to the patient's discomfort and lameness. Unfortunately, not all elbow pathology is evident on radiographs, which is why we recommend arthroscopic evaluation. In our study, almost 75 percent of the participants had concurrent elbow pathology, more than half of whose radiographs were clean.

DIAGNOSTIC ULTRASOUND

VOSM uses diagnostic musculoskeletal ultrasound definitively diagnose ST. Because it can be challenging to identify the lesion, it is imperative to have a board certified specialist experienced in small animal musculoskeletal ultrasonography

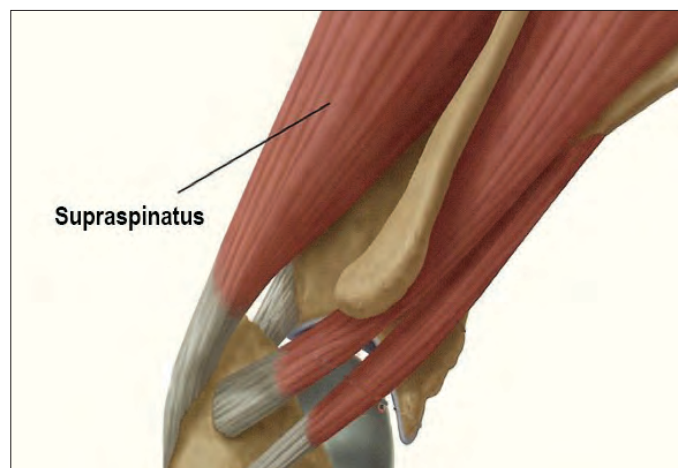


FIGURE 1. MEDICAL DRAWING OF NORMAL ANATOMY OF A DOG'S SHOULDER.

perform the ultrasound. We prefer diagnostic ultrasound to MRI because we are able to perform serial evaluations without sedating the patient and it is much less costly. Throughout treatment, serial ultrasound rechecks allow us to objectively measure response to treatment and best customize the patient's rehabilitation therapy program. [See Figure 2.](#)

MRI

MRI is also an excellent diagnostic modality for patients with ST. However, MRI requires the patient be placed under general anesthesia, is not conducive to serial evaluations, takes longer to perform, and costs much more. Because of that, we almost always prefer diagnostic ultrasound to MRI.

Arthroscopy

In our study, 91 percent of dogs presented with concurrent shoulder pathology that cannot be identified on ultrasound but can be seen arthroscopically. We also found that 75 percent of dogs had concurrent elbow pathology, which also cannot be identified on ultrasound.

Without identification and treatment of these pathologies, discomfort and lameness may persist despite appropriate treatment of the supraspinatus tendinopathy. Fortunately, all of these pathologies can be simultaneously diagnosed and treated arthroscopically. [See Figure 3.](#)

HOW IS ST TREATED?

Regenerative Medicine Therapy

Conservative management — rest, non-steroidal anti-inflammatory medications (NSAIDs) and rehabilitation therapy — often fails. This is because, in chronic tendinopathies, there is no active inflammation occurring. Though it may seem counterintuitive, we need to stimulate the tendon (create inflammation) to restart the healing process. In addition, rehabilitation therapy

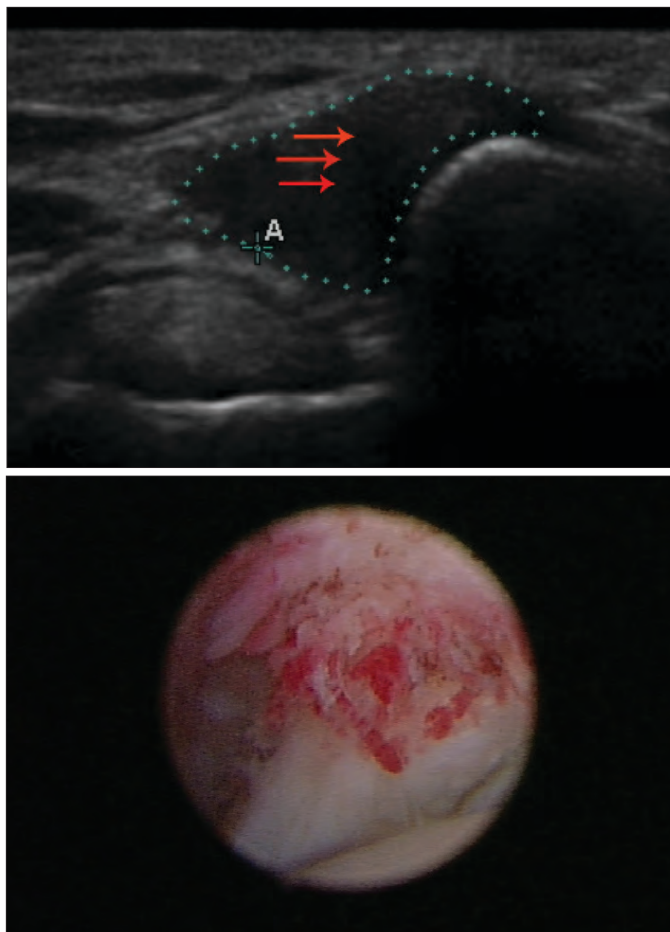


FIGURE 2. ULTRASOUND IMAGE OF A SUPRASPINATUS TENDINOPATHY WITH A CORE LESION (RED ARROWS). FIGURE 3. ARTHROSCOPIC IMAGE OF A SUBSCAPULARIS TENDINOPATHY.

relies on healing through scar tissue formation. Scar tissue does not have the strength or flexibility of normal tendon tissue, increasing the potential for tendon re-injury and breakdown. Because conservative management often fails, and regenerative medicine has proven effective in treating tendinopathies in humans and horses, we have successfully adopted this method of treatment for dogs.

Regenerative medicine includes stem cell therapy, the act of using cells from the patient's own body to help decrease pain and inflammation and allow injured tissues to heal through regeneration. By introducing new "adult" stem cells through a targeted, minimally invasive approach, the damaged or diseased tissues are treated with minimal risk of rejection or side effects.

Stem cell therapy allows for healing through regeneration with targeted treatment directly to the lesion. Because tendon integrity isn't compromised by scar tissue, patients are able to return to full activity and function.

Stem cells are obtained from a fat sample collected from a small incision in the abdomen. The fat sample is sent to a regenerative medicine lab for processing. Within 10 to 14 days, the stem cells are returned to VOSM and are injected into the lesion under ultrasound guidance. In some cases, stem cells can be processed in-house and injected the same day. If concurrent conditions were noted at the time of arthroscopy, stem cells are also injected into the affected joints.

Additional information on stem cell therapy can be found in our Stem Cell Therapy In Dogs document (white paper).

Rehabilitation Therapy

Rehabilitation therapy is vital for enabling a return to full function following stem cell therapy. Tissue healing is the first step in the recovery process. If medial shoulder syndrome was noted and treated via arthroscopy, the patient is placed in an orthopedic device, such as forelimb hobbles, to protect the healing and regenerating tissues. See Figure 4.

During this phase, rehabilitation therapy focuses on preservation of range of motion, addressing not only the tendinopathy, but any compensatory issues as well. Once the tissues have healed, rehabilitative therapy focuses on muscle strengthening and reconditioning for long-term tissue protection from re-injury.



FIGURE 4. DOG WITH CONCURRENT SHOULDER PATHOLOGY PLACED IN HOBBLER AS PART OF THE POST-OP REHAB PROGRAM.

Some common rehabilitative modalities (i.e. Class IV laser therapy, shock wave therapy, therapeutic ultrasound and the use of NSAIDs) are contraindicated for regenerative medicine patients because they can inhibit stem cell growth and/or decrease response to treatment. Because of this, only a certified rehabilitation therapist (CCRP/CCRT/PT) and/or a board certified specialist from the American College of Veterinary Sports Medicine & Rehabilitation with regenerative medicine experience should oversee your dog's rehabilitation therapy program.

HOW LONG IS THE RECOVERY PROCESS?

Tissue healing requires about three months. In less than 10 percent of cases, a second injection may be necessary to achieve complete healing. Once tissues are healed, we recommend one to two months of rehabilitative therapy focused on strengthening and conditioning before return to full activity.

WHAT'S THE NEXT STEP?

If you believe your pet has ST or wish to obtain more information, we recommend taking the following steps:

- Schedule a consultation with Dr. Canapp to review your dog's history and perform a complete orthopedic evaluation and objective gait analysis.
- A definitive diagnosis will be determined based on results of the orthopedic evaluation and advanced diagnostics. For out-of-state and international patients, it is recommended that the consultation and potential diagnostics and/or treatments be booked the same day or following day for convenience. Our Surgical Coordinators can assist with scheduling.

- If you are interested in learning more or scheduling a consultation, please contact our Surgical Coordinators. Sending x-rays, blood work, MRI reports, etc. in advance will help us prepare for your consultation. This can be either emailed to the Surgical Coordinators or faxed to 240-295-4401.
- VOSM is conveniently located between Baltimore and Washington, DC. It is only 20 minutes from Baltimore-Washington International airport and within an hour of Dulles International and Reagan National airports. There are several dog-friendly hotels in the area with shuttle services to and from VOSM, if needed.

References

1. Canapp S, Barrett J, Brown J, Gavin P. Supraspinatus Tendinopathy in Dogs; 122 Cases. Presented at 2012 Association for Veterinary Orthopedic Research and Education Conference. Accepted for presentation at the upcoming 2012 American College of Veterinary Surgeons Symposium. Abstract available upon request.
2. Biologic approaches to enhance rotator cuff healing after injury. Isaac C, et al. Stem Cell Research Center, University of Pittsburgh, Pittsburgh, PA, USA, . J Shoulder Elbow Surg. Feb;21(2):181-90. 2012.
3. Exploring the application of stem cells in tendon repair and regeneration. Ahmad Z, et al. Arthroscopy. Jul;28(7):1018-29. 2012.
- 4 Cell- and gene-based approaches to tendon regeneration. Nixon AJ, Watts AE, Schnabel LV. J Shoulder Elbow Surg. Feb;21(2):278-94. 2012.
5. Cell therapy in tendon disorders: what is the current evidence? Obaid H, et al. Am J Sports Med. Oct;38(10):2123-32. 2010.
6. Regenerative medicine for the treatment of musculoskeletal overuse injuries in competition horses. Torricelle P, et al. Int Orthop. 2011 Oct;35(10):1569-76. 2011.