

# Dr. Canapp Performs Fluoroscopic Guided Arthroscopy On A Rare Australian Turtle For The National Aquarium



Little Terri, a member of the *Elseya irwini* species, had progressive degeneration within her left shoulder joint and her caretakers asked Dr. Canapp to help.

## Elseya irwini

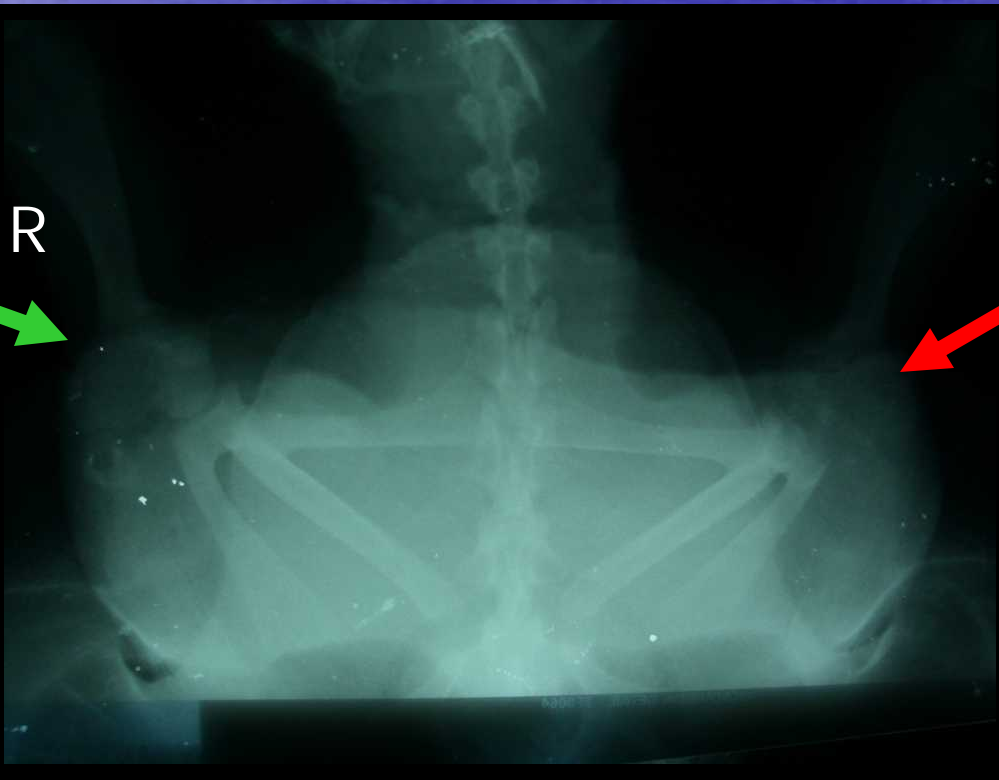Little Terri, a female freshwater Australian turtle, is of the species *Elseya irwini*. The species was named after its discoverers, famed zoologist and TV personality, Steve Irwin, *The Crocodile Hunter*, and his father Bob Irwin. During a family camping trip in 1990, Bob Irwin caught an unusual looking turtle while fishing. Steve Irwin took photos of the turtle and sent them to turtle expert John Cann. The turtle was thought to be a new species. Unfortunately, this suspicion was confirmed after the tragic death of Steve Irwin. Little Terri was named in honor of Terri Irwin, Steve Irwin's widow.

This species of turtle is unique in that it can breathe underwater by taking water into its cloaca. A chamber with gill-like structures situated in the cloaca can extract oxygen from the water allowing the turtle to stay underwater for long periods without taking a breath.

# Little Terri's Clinical History

Little Terri, estimated to be 25+ years old, weighing 3.8kg (about 8lbs), was suffering from chronic progressive lysis (bone loss) of her left shoulder joint. Her caretakers at the National Aquarium of Baltimore, Dr. Leigh Ann Clayton, Director of Animal Health, and Dr. Kat Hadfield, an Associate Veterinarian, noted these changes on x-rays and followed up with a CT performed at Johns Hopkins. When they saw the disease was progressing they decided tissue samples were needed to determine the cause of the destruction in Little Terri's shoulder.

Normal  
Shoulder  
Joint



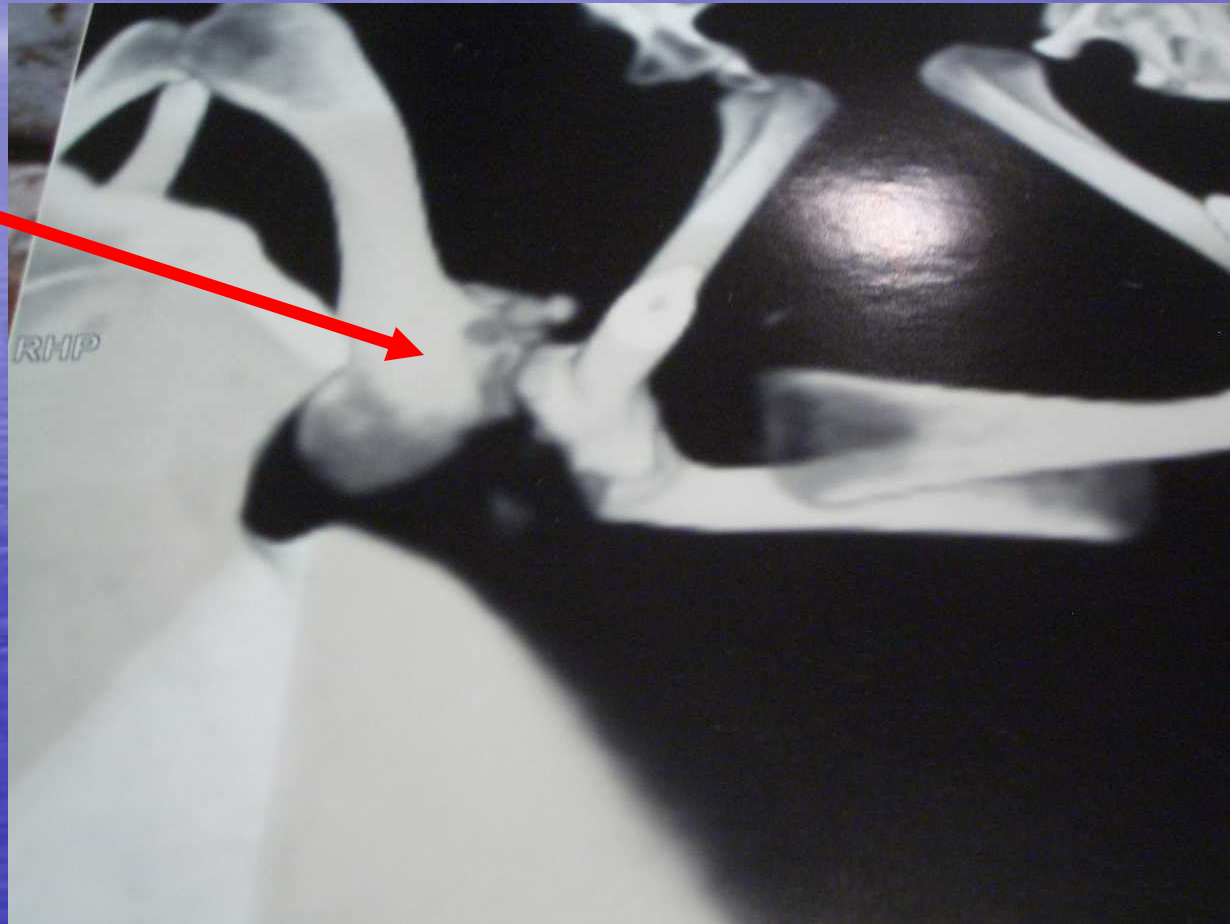Abnormal  
shoulder  
joint.

Note the  
absence of  
bone



# Little Terri's Shoulder As Imaged By CT with 3-D Reconstruction

Note the bony remodeling and destruction within the shoulder joint.



Little Terri's caretakers could have opted for an open surgery to obtain the needed tissue samples, however, they wanted to minimize the trauma to Little Terri's joint and her recovery time.

Dr. Clayton contacted Dr. Canapp who is a consultant for the National Aquarium and known for his expertise in minimally invasive surgery to see if he could help. Dr. Canapp was provided the x-rays, CT, and information about the anatomy of turtle shoulders. Dr. Canapp immediately offered his services. The Aquarium provided a cadaver turtle about the same size as Little Terri. Dr. Canapp was successful in scoping the cadaver turtle's shoulder and a week later performed fluoroscopic guided arthroscopy on Little Terri.

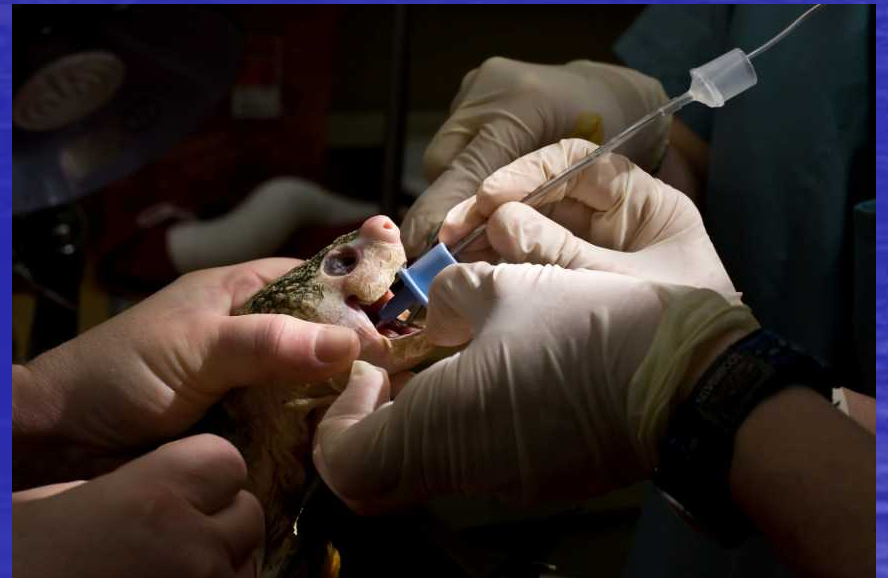
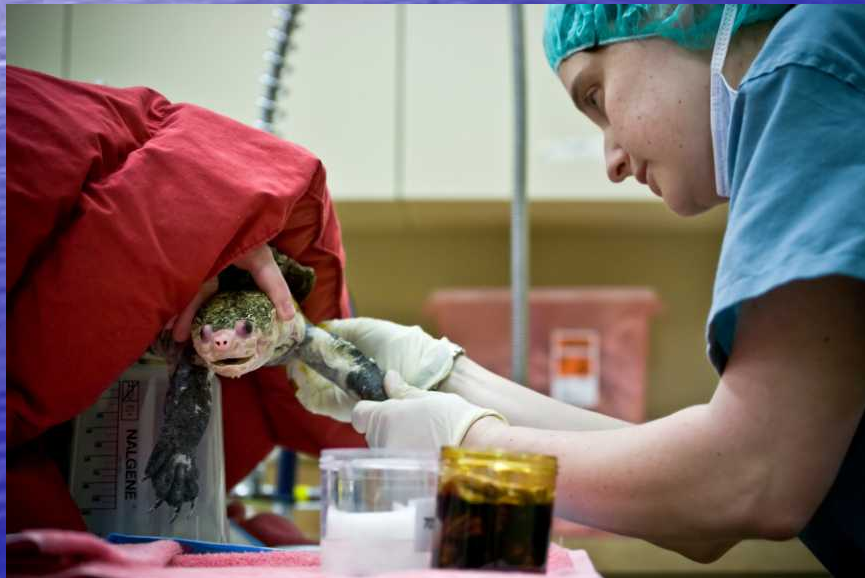Little Terri arrived at VOSM with her team from the Aquarium. The team prepared Little Terri for surgery and monitored her during her surgery and recovery.

Dr. Canapp, assisted by VOSM Surgical Technician, Mindy Willis successfully performed the arthroscopy and obtained tissue samples for histopathology and culture.

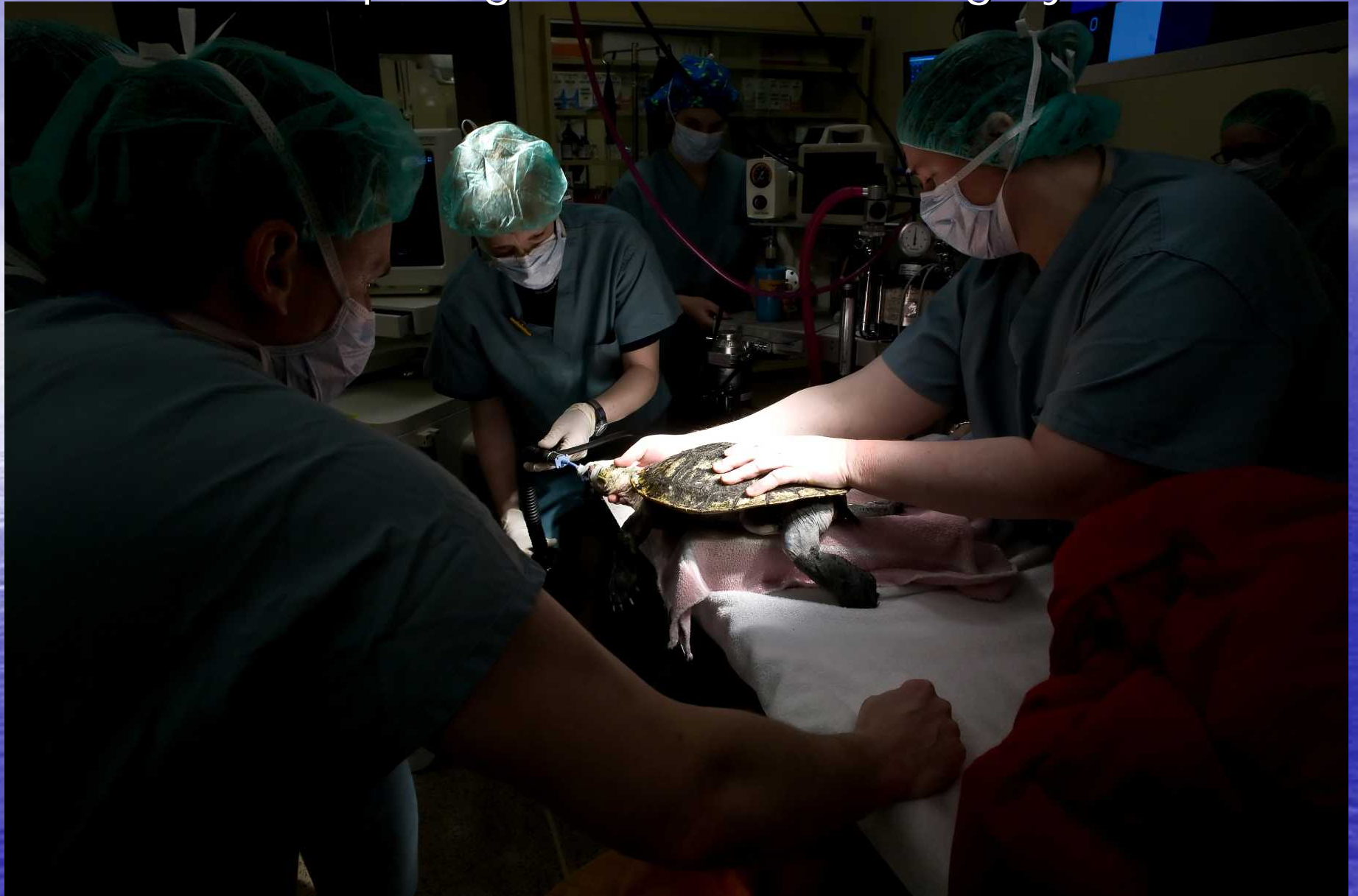Dr. M. Chris Zink, a VOSM Consultant, is a pathologist at Johns Hopkins. She examined the samples obtained by Dr. Canapp and provided Little Terri's diagnosis.



# Preparing Little Terri for Surgery

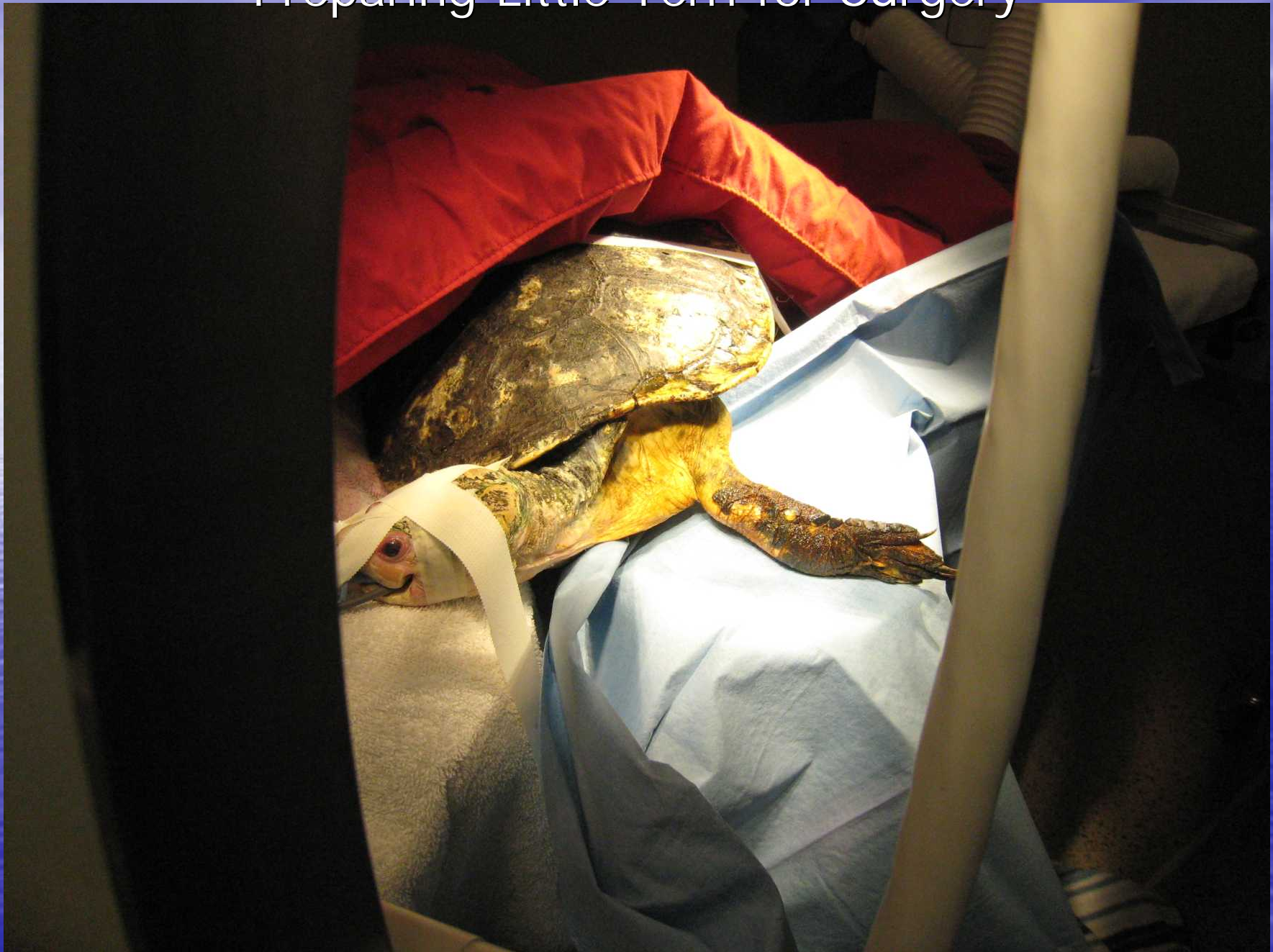


# Preparing Little Terri for Surgery





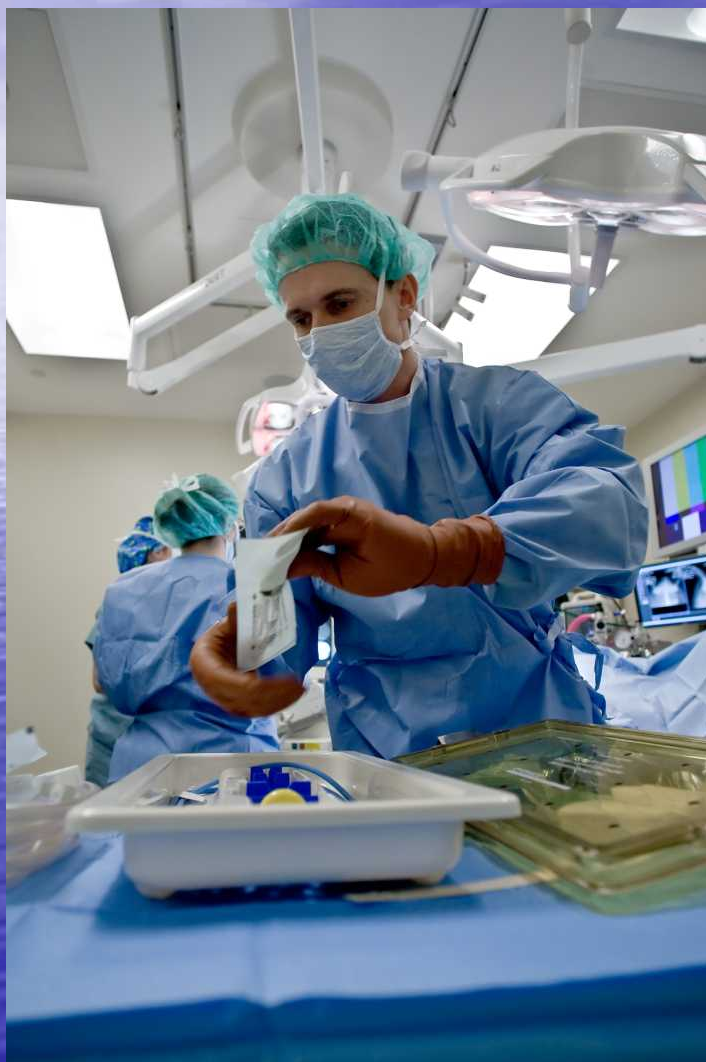# Preparing Little Terri for Surgery



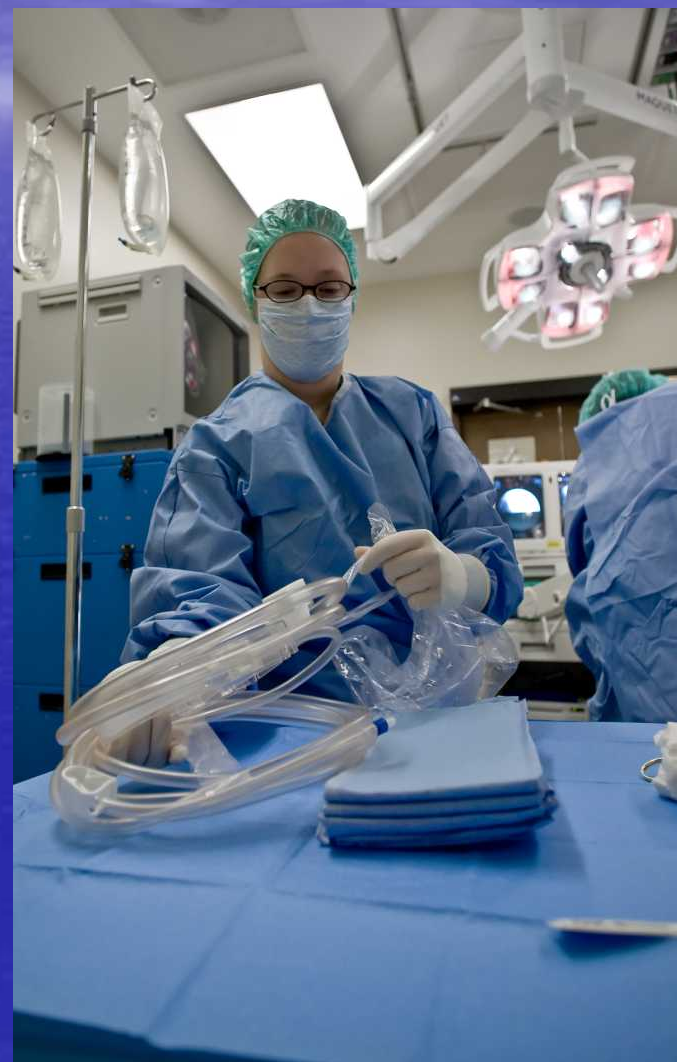

# Setting Up the Arthroscopy Instruments

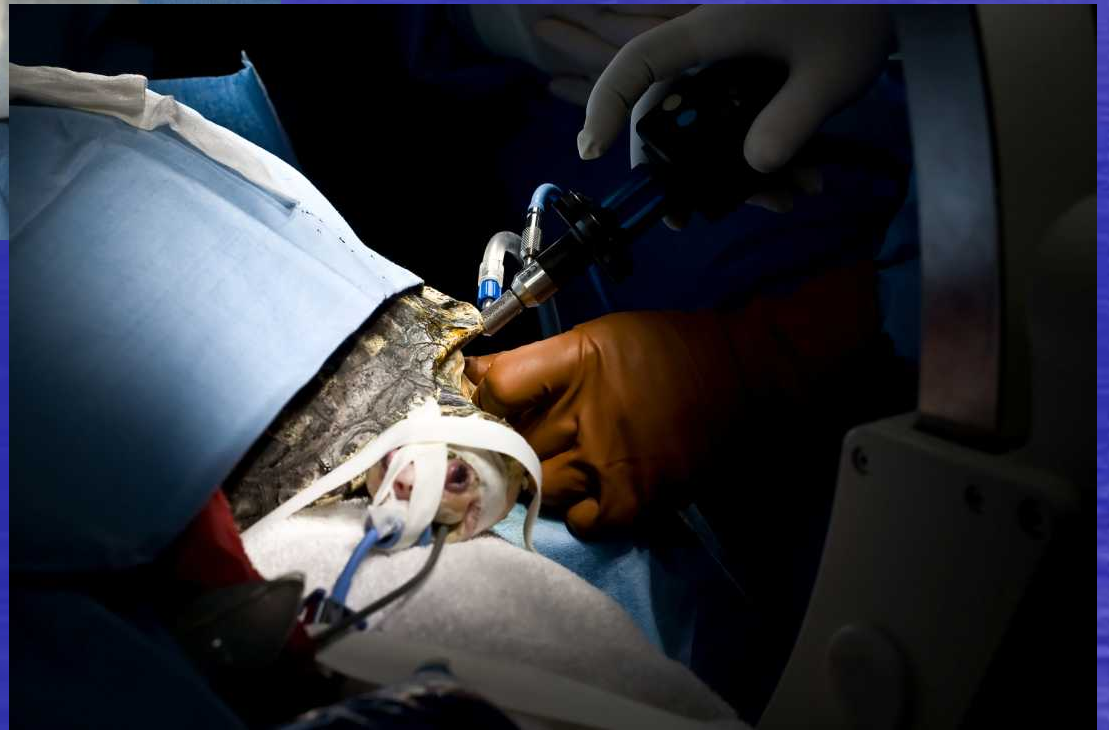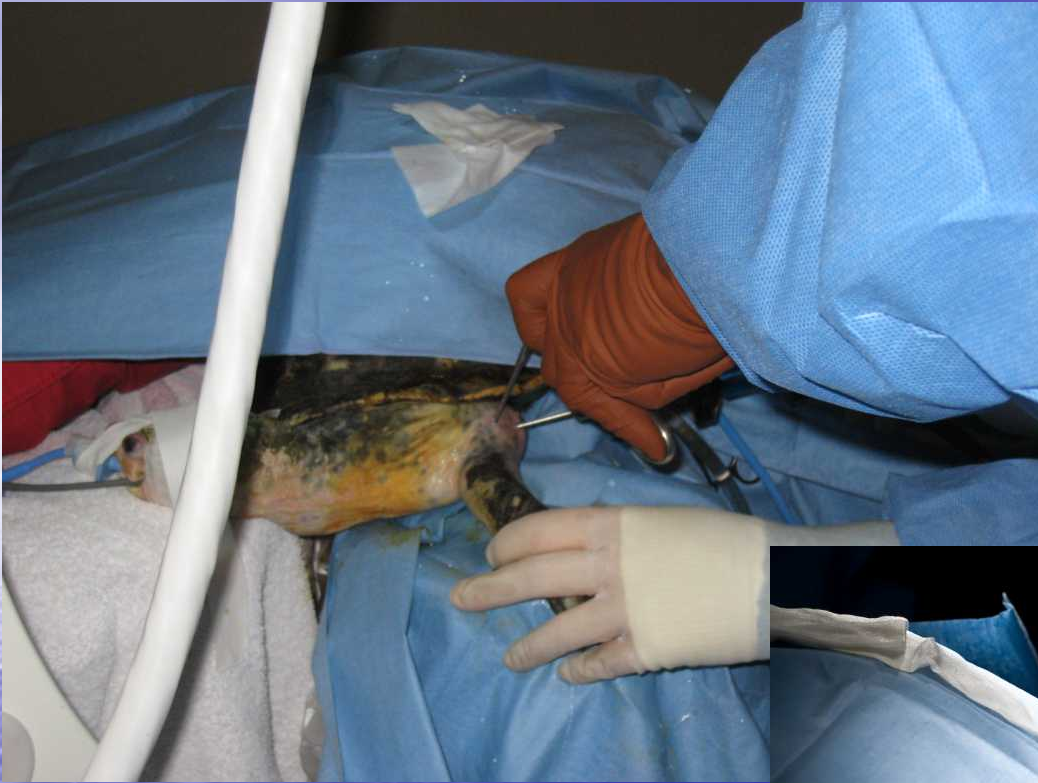Dr. Sherman Canapp



Mindy Willis

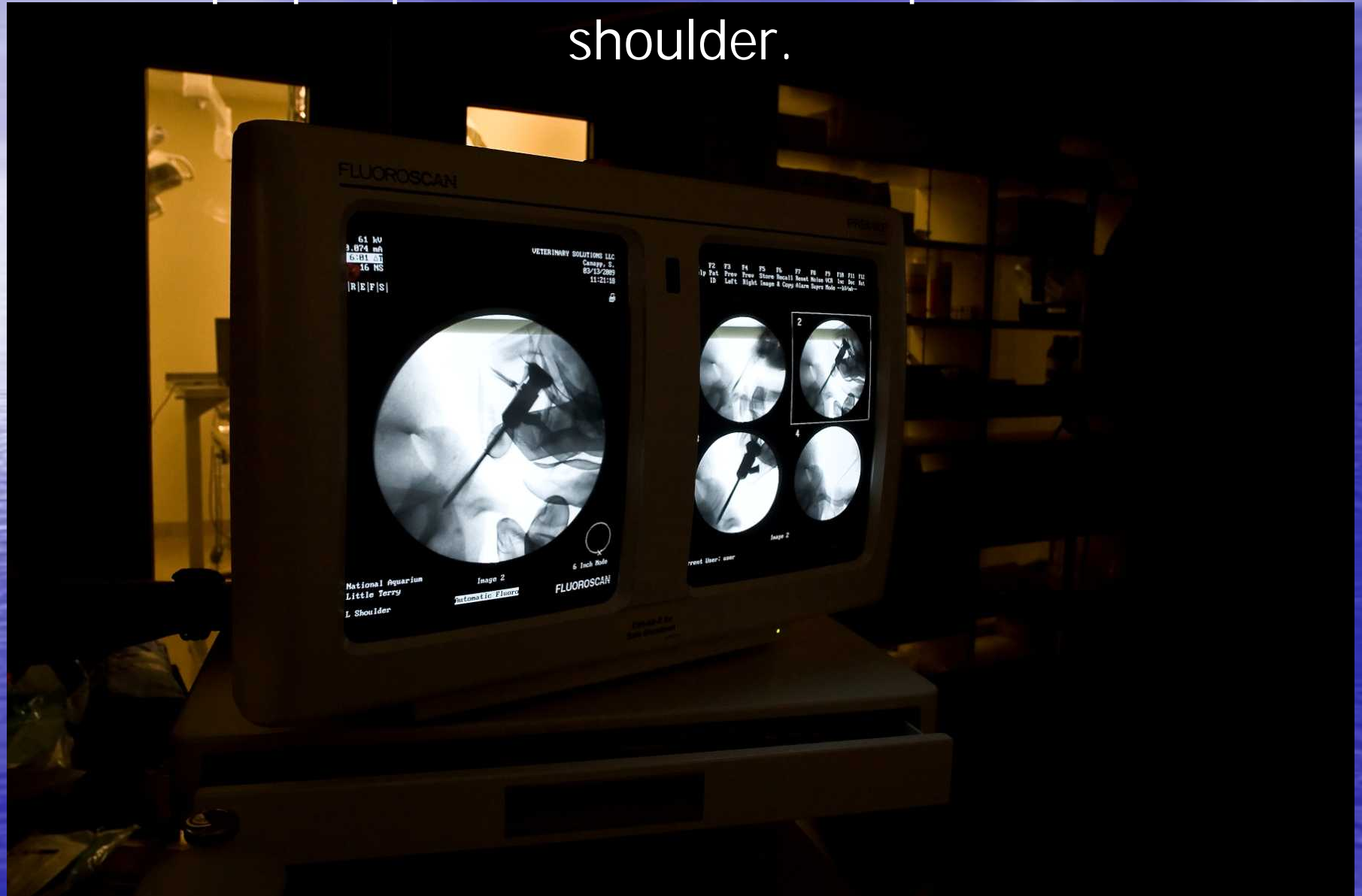

Dr. Canapp positions the scope in Little Terri's shoulder.

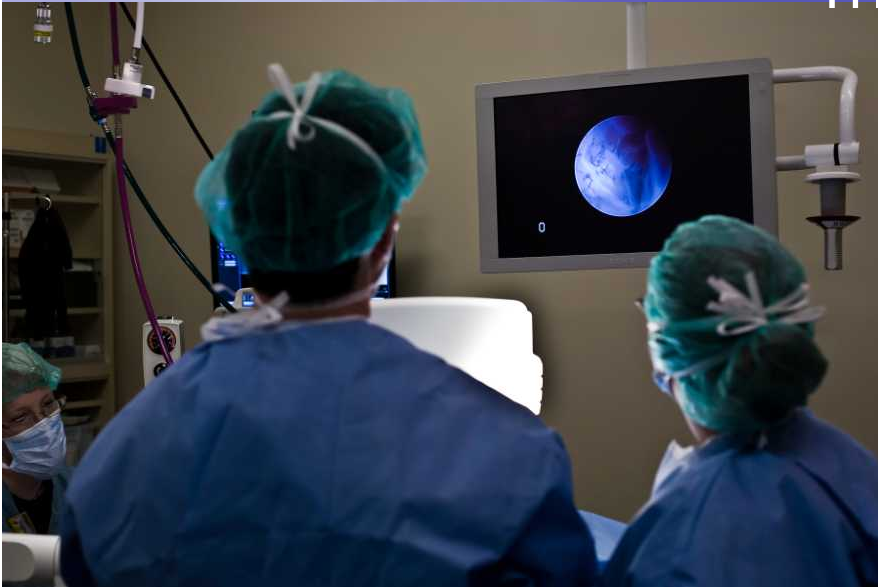



Dr. Canapp utilizes fluoroscopy (real time x-ray) to ensure proper placement of the scope in Little Terri's shoulder.

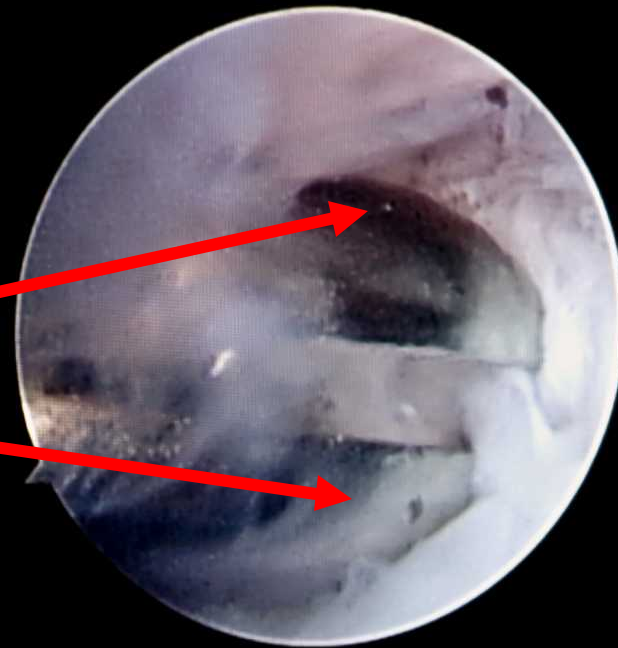


Images of Little Terri's shoulder are viewed on a monitor.



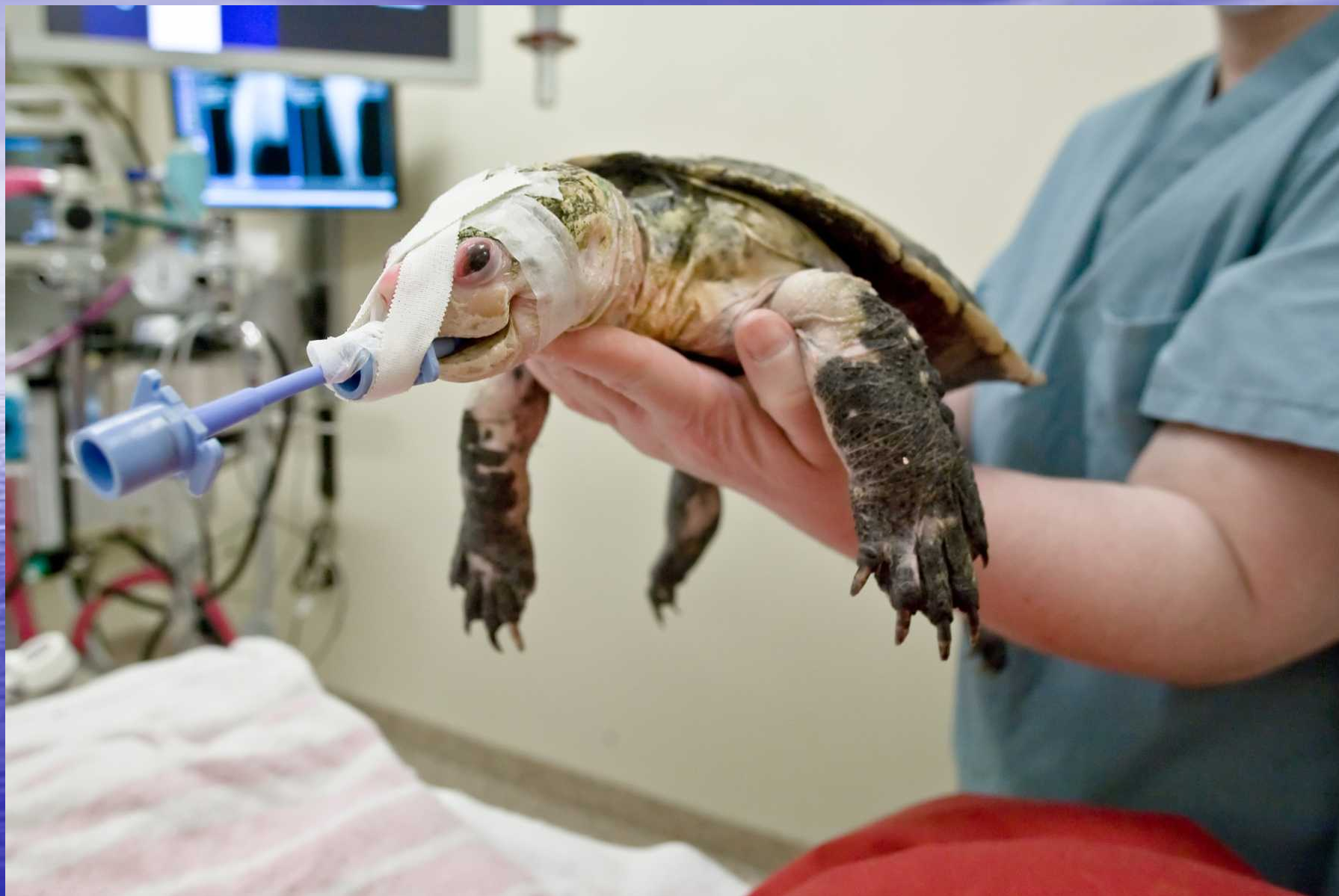Tissue samples were obtained through arthroscopy and were submitted to Johns Hopkins for evaluation.

Note the black specs present within the joint.

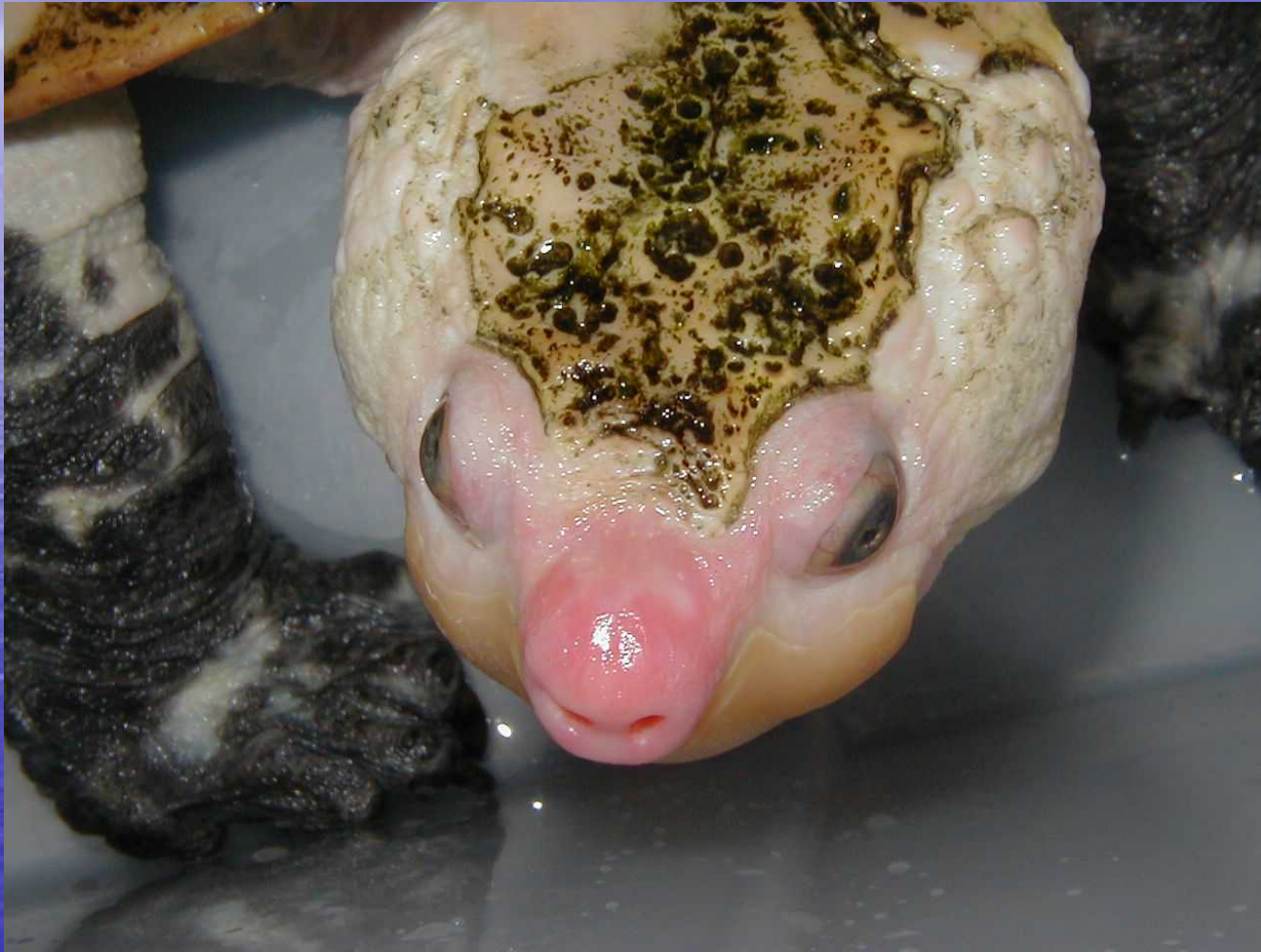



Little Terri being moved from the surgery suite to recovery.



Little Terri recovered quickly and later that day ate well and returned to the water.





## Little Terri's Diagnosis

- A degenerative process was found, the changes within Little Terri's shoulder are not due to neoplasia (cancer).
- The humeral head consisted of completely normal cancellous bone with normal bone marrow.
- Other sections clearly showed at least one and probably several ruptured tendons/ligaments (ligaments and tendons cannot be differentiated on histopathology).
- The black flecks seen on arthroscopy were accumulations of macrophages containing melanin pigment, which is typical of inflammatory reactions in amphibians.
- Cultures are still pending.

Little Terri is being currently being treated with anti-inflammatory medications and is doing well.