

# Carpal and Tarsal Injuries

By Gayle H. Jaeger, DVM, MSpVM, DACVS and Sherman O. Canapp Jr., DVM, MS, DACVS

Injuries to the carpal and tarsal joints are common in performance dogs. These joints act as shock absorbers during weight bearing and are prone to injury due to their anatomic complexity and lack of muscular support. It is this complexity that creates a diagnostic problem for many veterinarians, and many carpal and tarsal injuries, particularly those that go undiagnosed or untreated, can result in an increased risk of osteoarthritis and potential long-term lameness.

## Anatomy

**Figure 1** illustrates the anatomy of the carpus and **Figure 2** the tarsus: these are multilevel joints with several supportive ligaments and a joint capsule. The carpus is composed of three articulations: the antebrachiocarpal joint, the middle carpal joint, and the carpometacarpal joint. The majority of carpal range of motion (70%) is at the antebrachiocarpal joint, while the middle carpal and carpometacarpal joints have minimal range of motion. A thick fibrocartilage pad on the underside of the joint attaches to the individual carpal and metacarpal bones. The main supportive ligaments of the carpus include the medial (radial) and lateral (ulnar) collateral ligaments, which support each side of the joint, and numerous dorsal (upperside) and palmar (underside) ligaments.

Similarly, the tarsal joint is complex and composed of four articulations: the tibiotarsal joint, proximal (top) intertarsal joint, distal (bottom) intertarsal joint, and tarsometatarsal joint. The majority of tarsal range of motion (80%) occurs at the tibiotarsal joint. The tarsal joint is supported by numerous ligaments, including the medial and lateral collateral ligaments, dorsal (upperside) and plantar (underside) ligaments.

## Cause of Injury

Carpal and tarsal injuries can result from either acute traumatic events or activities that cause sudden repetitive sprains to the joints' supportive structures. Possible modes of injury include hyperextension (the most common type seen in agility dogs), hyperflexion with rotation, varus (inside of the limb) or valgus (outside of the limb) injuries, degeneration of ligaments in some breeds (Collies and Shelties), and certain immune-mediated diseases such as rheumatoid arthritis.

## Diagnosis

Diagnosing mild carpal and tarsal injuries can be difficult, but is possible using a combination of physical examination and imaging techniques. Dogs with carpal or tarsal injuries can present with either acute

(sudden) or chronic (slowly progressive) lameness of varying degrees depending on the severity of the injury as shown in **Figure 3**. Palpation of the affected joint may reveal soft tissue swelling, discomfort, crepitus (crunching on manipulation), decreased range of motion, or instability when stressed (either in extension, flexion, varus or valgus, internal or external rotation). Palpation of the nonaffected joint on the opposite limb can be helpful in determining normal from abnormal motion.

X-rays can be taken to evaluate the type and severity of injury as seen in **Figure 4**. Although you cannot see ligamentous structures on x-rays, you can see bone fractures, luxations (dislocations or misalignments), and abnormal opening of a joint when stressed (extension, flexion,

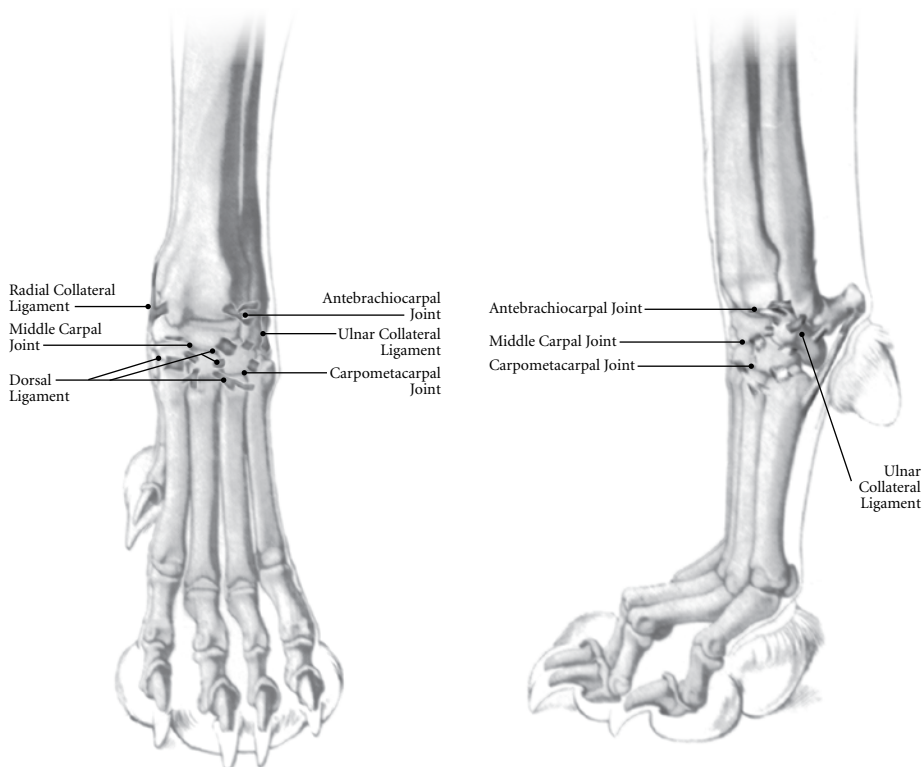


Figure 1. Canine Carpus (front foot)

COURTESY OF DR. DON HILFSE



Figure 3. Dog that has sustained a left forelimb carpal hyperextension injury.

COURTESY OF DR. DON HILFSE

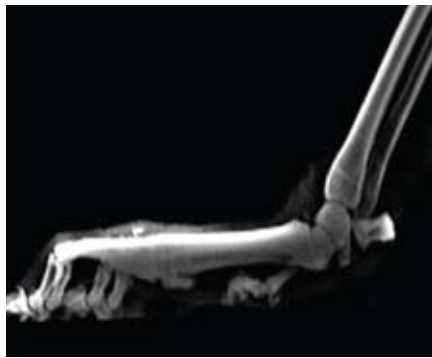

Figure 4. X-ray of a dog with a carpal hyperextension injury.

varus or valgus), which can help determine ligament integrity. Chronic or repetitive injuries may have bone spurs where ligaments attach, and those will also show up in an x-ray.

Fluoroscopy, which is performed in “real time,” takes an x-ray movie while you put the joint through its range of motion. It can show excessive openings of the joint spaces or abnormal gliding (subluxation) in carpal and tarsal injuries. When available, fluoroscopy is preferred over “stress” x-rays to evaluate carpal or tarsal joint motion during manipulation. If there is carpal or tarsal pain without x-ray abnormalities, an MRI (magnetic resonance imaging) or arthroscopy can be useful in diagnosing minor ligament sprains.

### Types of Injuries

Carpal and tarsal injuries can be classified into sprains, luxations, fractures, or a combination of the three. Sprains are the most common injuries in performance dogs, and sprains to the carpal and tarsal joints are the most likely to go undiagnosed. A sprain is an injury to a ligament that can occur in the midportion of the ligament or at its attachment to bone. Sprains are graded by severity. Grade 1 sprains are mild and described as an overstretching of the ligament, without a tear or loss of function. Grade 2 sprains are moderate in severity and are described as a partial tear. The general continuity of the ligament is intact though its strength is significantly reduced. Grade 3 sprains are severe and involve complete disruption or tearing of

the ligament, resulting in joint instability. Since ligaments have a poor blood supply and require the formation and organization of collagen (scar tissue) for their repair, ligament healing times can be quite lengthy. Ligaments only regain about 60% of their original strength after one year. If a gap forms or is present at the junction of the ligament ends during healing, permanent ligament elongation and subsequent instability may result, even if an intact ligament reforms.

Luxation, or dislocation, involves the disruption of multiple ligaments and the joint capsule. In the carpus, the antebrachio-carpal joint is the most common site of luxation due to its increased range of motion and its conformation. In the tarsus, however, the intertarsal joints are commonly affected due to the relative lack of bone interdigitation of these joints compared to the tibiotarsal joint, which serves as an inherent joint stabilizer.

Common fractures associated with carpal and tarsal injuries in performance dogs include the attachment sites for the collateral ligaments (avulsion fractures) or bone fractures due to compression or shear forces. Fractures at these sites result in joint instability when stressed on palpation or during weight bearing. Another fracture site is the accessory carpal bone in the front limb, where the flexor carpi ulnaris tendon attaches. A hyperextension injury can result in fracture of the accessory carpal bone where the tendon attaches, as well as damage to the palmar (underside) ligaments. Similarly, in the hind limb, fractures of the calcaneus (heel bone) can occur.

© GAYLE H. JAEGER

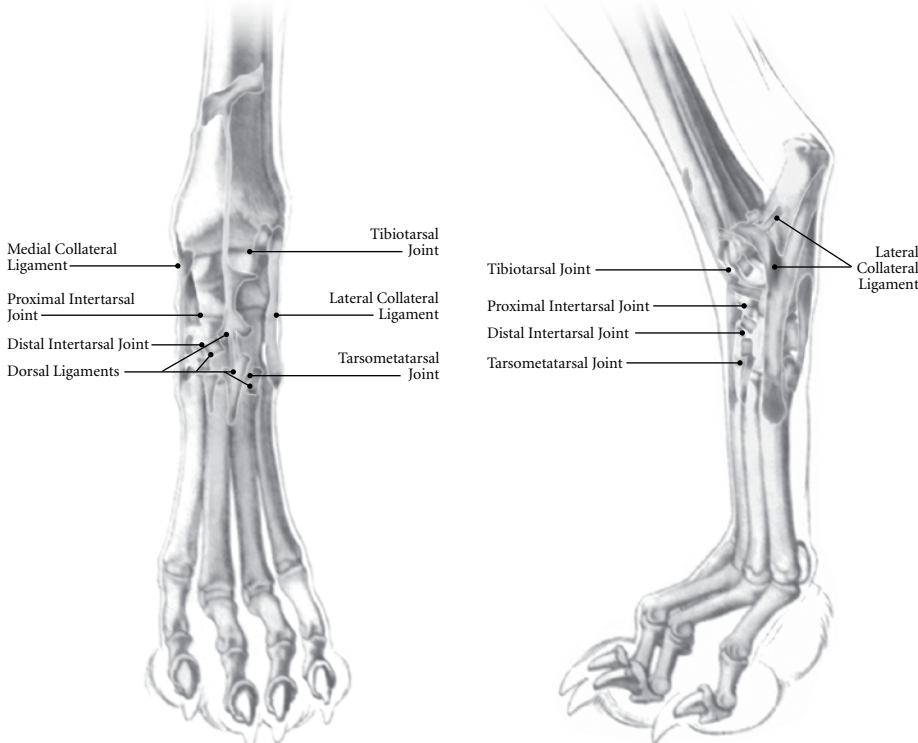


Figure 2. Canine Tarsus (rear foot)

Dr. Jaeger is a Diplomate of the American College of Veterinary Surgeons. She received her DVM degree from North Carolina State University, after which she completed an academic internship at Oklahoma State University and a specialized surgical internship in Orlando, Florida. She then completed a three-year residency at North Carolina State University, while earning a Masters degree in Specialized Veterinary Medicine. She has also been trained in rehabilitation through the University of Tennessee. Dr. Jaeger's interests include fracture and ligament repair and joint replacement. She is currently practicing orthopedic surgery at the Veterinary Orthopedic and Sports Medicine Group with Dr. Canapp.

Dr. Canapp, a Diplomate of the American College of Veterinary Surgeons, completed a combined D.V.M./M.S. at Kansas State University, an internship in small animal medicine and surgery at the University of Missouri, a three-year residency in small animal surgery at the University of Florida, and training in canine rehabilitation by the Canine Rehabilitation Institute. He currently practices orthopedic surgery and sports medicine at the Veterinary Orthopedic & Sports Medicine Group (VOSM) in Ellicott City, Maryland, and is a consultant to local zoos, police K-9 units, agility, flyball, and disc competition dogs. See additional information about Dr. Canapp at [www.vetsportsmedicine.com](http://www.vetsportsmedicine.com).

## Treatment

Treatment is based on the location and severity of the injury. Mild to moderate ligament sprains (Grades 1 and 2) are amenable to external support, using specialized wraps, orthotics, a splint, or a cast for six to eight weeks, in addition to rehabilitation therapy. Supportive bandages allow for joint immobilization, preventing further injury to the affected ligament and providing stability so the ligament can heal. Specialized support wraps and orthotics like those shown in **Figure 5** can be custom designed and manufactured for each individual dog. For more severe cases, an external fixator with a hinge can be placed above and below the injured joint. This allows the joint to heal, while at the same allowing controlled range of motion to strengthen the resulting repair. Unsupported or premature weight bearing during healing can result in an elongated ligament, negating the return of ligament strength and resulting in persistent instability. Nonsteroidal anti-inflammatory medications and cryotherapy (ice wraps) can be administered in the initial stages of the injury to improve comfort, reduce swelling, and facilitate overall limb use.

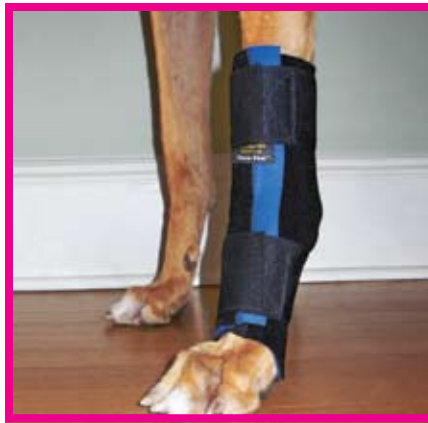

Figure 5. Carpo-flex support wrap for a carpal injury

Severe sprains or luxations causing instability (Grade 3) usually require surgery. Surgical options include primary repair of the torn ligament, the placement of a prosthetic ligament (suture) when primary repair cannot be performed, or a partial or complete arthrodesis (joint fusion).

Luxations of the middle carpal, metacarpal-phalangeal joint, intertarsal or tarsometatarsal joints, or disruption of the palmar or plantar ligaments can be stabilized with partial arthrodesis. This allows for stabilization of the joint while maintaining the majority of joint motion. When there is

instability of the antebrachio-carpal or tibio-tarsal joints, complete arthrodesis is usually necessary. Arthrodesis can be performed by long-term stabilization with an external skeletal fixator, plate and screws, or internal pins and wire. Surgical reconstruction or internal arthrodesis requires additional support from an external bandage for at least six weeks. Fractures warrant open surgical reduction and internal fixation (plate and screws or pins and screws). Internal fixation of fractures of the small bones of the carpi and tarsi can be difficult due to the small and irregular size of their bones.

## Prevention

Although carpal and tarsal injuries may occur due to repetitive activity and recurrent sprains, a majority of these injuries occur out of the ring. Jumping down from high levels is one of the most common causes of severe injury. Therefore, this activity should be avoided whenever possible. Agility dogs with chronic carpal and tarsal injuries may benefit from a custom support wrap during practice and competition. Unfortunately, however, few agility organizations allow dogs to compete with support wraps. 🐕

## Because he's not just a pet. He's an athlete.



Veterinary Orthopedic and Sports Medicine Group (VOSM) is committed to providing the highest quality veterinary Orthopedic surgery and rehabilitative care. VOSM is the only practice in North America with a:

- Board Certified Veterinary Orthopedic Surgeon trained in Canine Rehabilitation
- Veterinarian and Physical Therapist also trained in Canine Rehabilitation
- Veterinary Sports Trainer

Through the effective integration of science, compassion, and professional integrity, we relieve pain, regain movement, restore function, and promote health and wellness in your flourishing athlete. **We not only understand the demands that are placed on your athlete, we help him meet them.**

- Sports Medicine
- Minimally Invasive Orthopedic Surgery
- Gait Analysis & Retraining
- Rehabilitative Therapy

Entrust your best friend with the best in medical care.



10270 Baltimore National Pike Ellicott City, MD 21042 301-560-1397 or 410-418-8446 [www.vetsportsmedicine.com](http://www.vetsportsmedicine.com)